

Management of Humeral Shaft Fractures

Eben A. Carroll, MD
 Mark Schweppe, MD
 Maxwell Langfitt, MD
 Anna N. Miller, MD
 Jason J. Halvorson, MD

Abstract

Humeral shaft fractures account for approximately 3% of all fractures. Nonsurgical management of humeral shaft fractures with functional bracing gained popularity in the 1970s, and this method is arguably the standard of care for these fractures. Still, surgical management is indicated in certain situations, including polytraumatic injuries, open fractures, vascular injury, ipsilateral articular fractures, floating elbow injuries, and fractures that fail nonsurgical management. Surgical options include external fixation, open reduction and internal fixation, minimally invasive percutaneous osteosynthesis, and antegrade or retrograde intramedullary nailing. Each of these techniques has advantages and disadvantages, and the rate of fracture union may vary based on the technique used. A relatively high incidence of radial nerve injury has been associated with surgical management of humeral shaft fractures. However, good surgical outcomes can be achieved with proper patient selection.

From the Department of Orthopaedic Surgery, Wake Forest University, Baptist Medical Center, Winston-Salem, NC.

Dr. Miller or an immediate family member serves as a paid consultant to Synthes and has received nonincome support (such as equipment or services), commercially derived honoraria, or other non-research-related funding (such as paid travel) from Smith & Nephew. None of the following authors or any immediate family member has received anything of value from or owns stock in a commercial company or institution related directly or indirectly to the subject of this article: Dr. Carroll, Dr. Schweppe, Dr. Langfitt, and Dr. Halvorson.

J Am Acad Orthop Surg 2012;20:423-433

<http://dx.doi.org/10.5435/JAAOS-20-07-423>

Copyright 2012 by the American Academy of Orthopaedic Surgeons.

Fractures of the humeral shaft account for approximately 3% of all fractures.¹ In the United States, approximately 66,000 humeral shaft fractures occur annually. Most of these fractures occur in the elderly population and are the result of a fall; however, younger patients may sustain this injury secondary to penetrating or high-energy trauma.¹

Anatomy and Surgical Approach

The humeral shaft extends distally from the proximal border of the pectoralis major insertion to the supracondylar ridge. The spiral groove, which contains the radial nerve, is located posteriorly and serves as an important landmark. Cadaver studies have demonstrated that the radial nerve crosses the posterior aspect of

the humerus approximately 14 cm proximal to the lateral epicondyle,² and the nerve lies directly adjacent to the posterior aspect of the humerus for 6.5 cm. The nerve pierces the lateral intermuscular septum an average of 10 cm proximal to the lateral epicondyle, entering the anterior compartment. Given the proximity of the radial nerve to the osseous anatomy of the humerus, the nerve is at significant risk of injury in association with humeral shaft fracture.³

Surgical approach to the humerus is dictated by the anatomic location of the fracture (Table 1). The anterolateral approach is a distal continuation of the deltopectoral approach and splits the brachialis muscle. Although the laterally located radial nerve is protected from the lateral portion of the brachialis, identification of the nerve is imperative with more distal extension.⁴

Table 1**Surgical Approaches to the Humerus**

Fracture Location	Surgical Approach	Concerns and Limitations
Proximal	Deltopectoral	Axillary nerve Deltoid detachment Anterior humeral circumflex artery
Middle (Proximal)	Anterolateral (continuation of deltopectoral with splitting of brachialis muscle)	Radial nerve (distally between brachialis and brachioradialis) Brachialis split
Middle (Distal)	Posterior (triceps split)	Radial nerve Failure of adequate exposure proximally with triceps split technique
Distal	Posterior (triceps split or paratricipital)	Radial nerve Ulnar nerve (with medial exposure)
Extensile	Deltopectoral with anterolateral extension Posterior with triceps reflection ²	Axillary nerve, radial nerve Radial/ulnar nerves

(Adapted from Zlotolow DA, Catalano LW III, Barron OA, Glickel SZ: Surgical exposures of the humerus. *J Am Acad Orthop Surg* 2006;14(13):754-765.)

The posterior approach can provide excellent access to the posterior aspect of the humeral shaft for distal fracture patterns. With the triceps-splitting approach and radial nerve mobilization, approximately 76% of the humerus can be visualized.² Gerwin et al² showed that exposure of approximately 94% of the humeral shaft can be achieved using a modified posterior approach. The triceps can be mobilized from lateral to medial (paratricipital approach) or a triceps-splitting approach can be used.^{4,5} In the traditional triceps-splitting approach, the heads of the triceps brachii muscle are separated. Superficial dissection involves development of the interval between the lateral and long heads of the triceps; this exposes the deeper medial head, which is then incised and dissected subperiosteally to expose the humerus. The lateral paratricipital approach makes use of the tissue plane between the lateral head of the triceps and the lateral intermuscular septum. This approach has gained popularity because it avoids injury to the muscle, potentially resulting in decreased adhesion and scar formation as well as a decreased risk of denervation.⁴ Only 55% of the distal

humerus can be exposed without mobilization of the radial nerve; however, if the nerve is mobilized and the lateral head of the triceps is elevated laterally, 76% of the humeral shaft is accessible via the triceps-splitting approach.^{2,4} Regardless which approach is used, the radial nerve must be identified as it exits the spiral groove, and it must be protected throughout the procedure.

Initial Examination

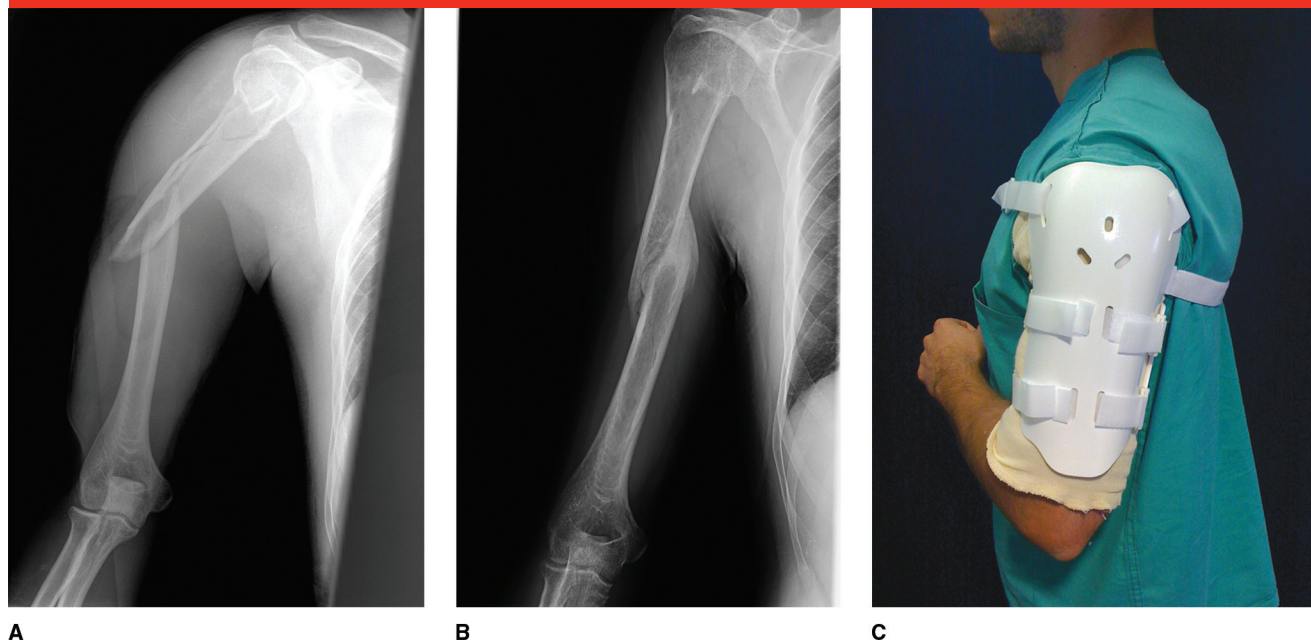
Initial patient assessment involves a complete physical examination with adherence to Advanced Trauma Life Support guidelines. Often, humeral shaft fractures are harbingers of other injuries, notably hepatic trauma, in polytraumatized patients.⁶ A thorough neurovascular examination of the affected extremity should be performed and documented before undertaking any intervention, including closed reduction or surgery. Orthogonal and plain radiographs of the shoulder and elbow are required to rule out concurrent injury. Advanced imaging such as CT is rarely necessary for humeral shaft fractures.

These fractures are often classified by anatomic location (proximal, middle, or distal third) and description (butterfly, comminuted, spiral, oblique). The AO fracture classification scheme, which is widely used and accepted, classifies fractures by type.⁷ Types A1, A2, and A3 are simple, spiral, and oblique fractures, respectively. Spiral wedge fractures, bending wedge fractures, and fragmented wedge fractures are classified as types B1, B2, and B3, respectively. Types C1, C2, and C3 (ie, complex spiral, complex segmental, and complex irregular fractures, respectively) are complex fractures.

Nonsurgical Management

Most humeral shaft fractures can be managed nonsurgically. Nonsurgical management relies on secondary bone healing and callus formation.⁸ Gravity helps to align the fracture, with compression imparted via bracing and hydrostatic pressure. A certain amount of malalignment is well tolerated by patients. Klenerman⁹ found that deformities, including those with <20° degrees of angulation in the sagittal plane, those with

Figure 1



A, AP radiograph of the humerus demonstrating a midshaft fracture. **B**, AP radiograph made at 3-month follow-up demonstrating healing and corrected angulation following management with a Sarmiento brace. **C**, Photograph of a patient wearing a Sarmiento brace.

<30° of varus or valgus angulation, or limb shortening <2 to 3 cm, are generally considered acceptable and compatible with good function. Varus angulation of up to 10° is common and is a result of both deforming fracture forces and bracing techniques, whereas valgus and sagittal plane malalignment is rare.¹⁰ Rates of union achieved with nonsurgical management vary, but rates >90% have been reported.¹⁰⁻¹²

Initial stabilization of humeral shaft fractures often includes coaptation splinting. Proper splint application is essential for adequate stabilization. Medially, the U-shaped splint should be placed as far into the axilla as possible, and the splint should extend past the deltoid and onto the neck laterally. Varus fracture angulation caused by termination of the axillary portion of the splint distal to the fracture is common. Potential deformity can be minimized by proper splint placement and use of a valgus

mold at the fracture site. Coaptation splinting may be poorly tolerated, and slings and posterior splints can be considered for management of proximal and distal fractures, respectively.

The functional bracing method pioneered by Sarmiento has become the mainstay of treatment for most humeral shaft fractures.¹¹ Functional bracing provides circumferential compression at the fracture site. The brace is typically applied 5 to 7 days postinjury, following a short period of coaptation splinting (Figure 1). Immediate elbow and wrist range of motion (ROM) is essential for successful therapy with a functional fracture brace. However, active shoulder motion is not permitted until the fracture is clinically stable to avoid increased angular deformity.¹¹ The brace must be kept snug by intermittent tightening. In a study of 620 patients with a diaphyseal fracture of the humerus treated with

functional bracing, Sarmiento et al¹¹ reported that 7 of 465 patients (<2%) with closed fractures and 9 of 155 patients (6%) with open fractures went on to nonunion following functional bracing. In this series, average time to union was 9 to 14 weeks in closed and open fractures, respectively.¹¹ Mild deformity was common; 70% of patients had ≤5° of angulation in the sagittal plane at final follow-up, and approximately 1% had apex anterior angulation >25°. Varus deformity was more common; 75% to 80% of patients had varus or valgus <10°, which was considered acceptable.^{10,11} Fracture location (proximal, middle, or distal fractures) did not appear to affect outcomes of functional bracing.¹¹

Although most patients do well with nonsurgical treatment, some reports suggest that overall functional outcome is somewhat lower than that of an uninjured population, and a significant number of patients con-

Table 2**Relative Indications for Surgical Management of Humeral Shaft Fractures**

Open fracture
 Associated articular fracture
 Neurovascular injury
 Floating elbow
 Impending pathologic fracture
 Polytrauma
 Failure of closed management (bracing is not tolerated or provides inadequate alignment)

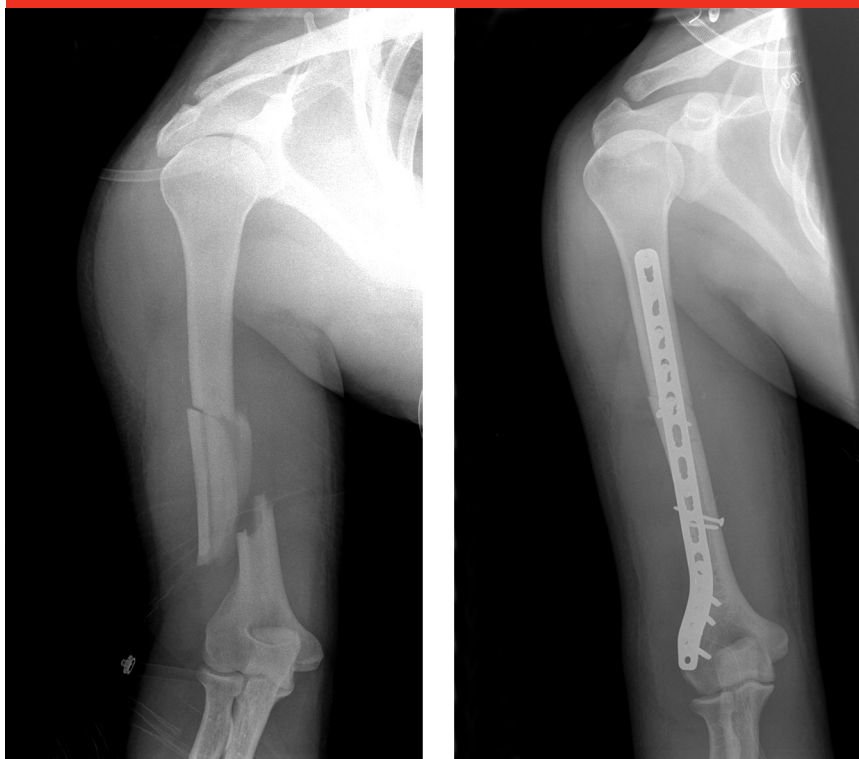
tinue to have activity limitations.^{10,12}

Surgical Management

Surgical management is indicated in several clinical scenarios (Table 2). Failure to achieve acceptable alignment with an adequate trial of bracing is one indication for surgical intervention (Figure 2). This is particularly true of varus angulation, which may cause difficulty with functional shoulder abduction. Certain fracture patterns may have a higher risk of failing nonsurgical management, including AO type A and proximal humerus fractures.^{10,12} In a retrospective review of 32 patients with nonunions following a trial of functional bracing, Ring et al¹³ found that most of the original fracture patterns were either oblique or spiral.

Open fractures are often managed surgically, with soft-tissue and bone débridement and stabilization to decrease further tissue trauma. Surgery should be considered for polytraumatized patients and those with fractures that involve the ipsilateral humeral articular surfaces (ie, shoulder, elbow, floating elbow) to prevent prolonged immobilization and facilitate self-care (Figure 3).

Few studies have compared surgical and nonsurgical management of

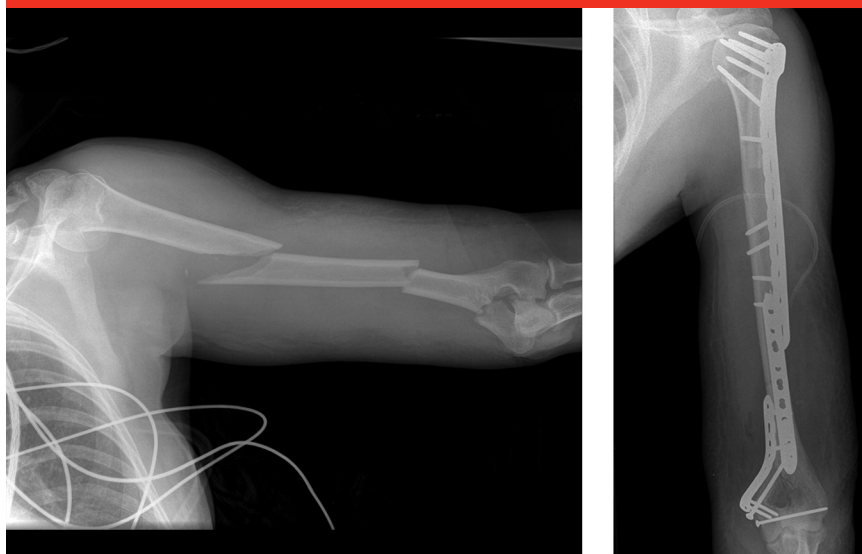
Figure 2**A****B**

A, AP radiograph demonstrating a fracture of the distal one third of the humerus. Alignment was not obtained with bracing and the limb was appreciably shortened (2.5 cm). The patient underwent surgical fixation within 2 weeks of injury after failure of brace treatment and discussion with the patient of treatment options. **B**, Postoperative AP radiograph of the humerus demonstrating anatomic alignment.

humeral shaft fractures. Wallny et al¹⁴ retrospectively compared 44 patients with humeral shaft fractures treated with functional bracing (group 1) with 45 patients treated with a locking intramedullary (IM) nail (group 2). Nonunion occurred in two patients in group 1 and in no patients in group 2. At final follow-up, 38 of 44 patients (86%) in group 1 had unrestricted shoulder movement compared with 22 of 45 patients in group 2 (48%). In addition, two patients from the IM nailing group required reoperation for infection and hematoma. Denard et al¹⁵ retrospectively reviewed 213 patients with humeral shaft fractures treated with functional bracing or compres-

sion plating. The rates of nonunion and malunion (defined as angulation >20° in any plane on radiographs) were greater in the nonsurgical group than in the surgical group (20.6% versus 8.7%, 12.7% versus 1.3%, respectively). However, there were no significant differences between the two groups with regard to time to union, infection, or iatrogenic radial nerve palsy. In a retrospective review of diaphyseal fractures of the distal one third of the humerus, Jawa et al¹⁶ treated patients with either open reduction and internal fixation (ORIF) or bracing. The authors reported that all of the fractures managed with functional bracing united, and there was no sta-

Figure 3



A

B

A, Preoperative AP radiograph demonstrating a segmental humeral shaft fracture with associated proximal and distal fractures. A deltopectoral approach was used with anterolateral extension to access the proximal segments, and a posterior extensile approach was used to access the distal segments. **B**, Postoperative AP radiograph of the humerus following plate fixation.

tistical difference in shoulder or elbow ROM between the two groups.

External Fixation

With the advent of improved surgical techniques, definitive management of humeral shaft fracture with external fixation has become rare. Soft-tissue injuries, burns, and fractures that require immediate stabilization are relative indications for external fixation. For example, in a patient with multiple long bone fractures and shock, temporary external fixation may be used during a vascular repair. External fixation is a temporary measure commonly used before more definitive management. Complications associated with external fixation include damage to neurovascular structures via percutaneous pin placement and high risk of infection.

Thorough knowledge of the cross-sectional anatomy is critical for safe placement of an external fixator. For

example, when external fixation is used to manage a midshaft fracture of the humerus, it is important to place the proximal pin through the anterolateral fibers of the deltoid, taking care to avoid the axillary nerve proximally as well as the long head of the biceps and the more medially located neurovascular structures. Pin placement in the middle third of the humeral shaft should be avoided given the lack of a distinct, anatomically defined safe zone in this area. In the distal one third of the humeral shaft, pins are inserted posteriorly through the triceps and parallel to the joint line, with care taken to avoid the radial and ulnar nerves and the olecranon fossa. For distal third fractures, pins are placed posteriorly through the triceps after palpating the ulnar nerve; the pins are inserted medial to lateral and parallel to the joint line. A generous incision is required to facilitate visu-

alization of structures at risk of injury during pin insertion.

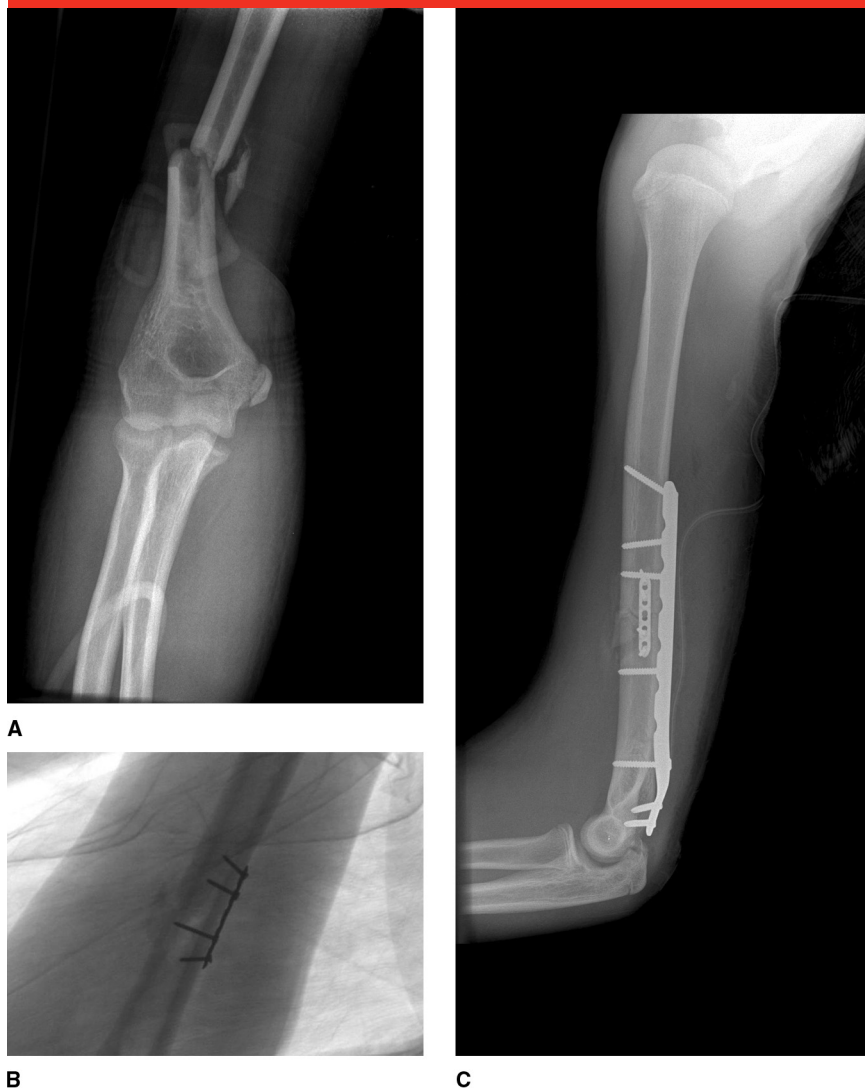Open Reduction and Internal Fixation

Plate-and-screw fixation allows direct visualization, anatomic reduction, and interfragmentary compression of the fracture and facilitates identification, exploration, and protection of the radial nerve. In addition, neither the shoulder nor elbow joint is violated, thereby preserving function and motion. Careful attention should be paid to minimize soft-tissue stripping and to achieve compression and rigid stabilization. Fracture gaps are poorly tolerated in the humerus and should be avoided. Postoperatively, immediate ROM of both the shoulder and elbow are allowed.

Disadvantages of plate fixation include larger dissections, possible soft-tissue stripping, and the potential for iatrogenic injury to the radial nerve. Therefore, adherence to standard AO principles of anatomic fracture reduction and preservation of soft tissue are imperative. Several devices, such as reduction clamps, Kirschner wires, and small plates, can be used to help maintain the reduction until final plate fixation can be performed (Figure 4). Spiral, oblique, or butterfly fragments may be amenable to lag screw fixation if care is taken to avoid devascularization of the fragments. Highly comminuted fractures are typically managed using a bridge plating technique in which the plate spans the comminuted fracture, with care taken not to disturb fracture biology.

Historically, stabilization of the fracture with eight cortices of fixation and a minimum of three to four screws inserted proximal and distal to the fracture was recommended.⁸ However, more recent studies have reported that the working length of

Figure 4



A, Preoperative AP radiograph demonstrating a distal third fracture of the humerus in a polytraumatized patient. **B**, Intraoperative fluoroscopic image demonstrating placement of a miniature fragment plate, which helped to reduce the fracture and improved stability during definitive fixation. This plate may be removed during definitive fixation, particularly if it impairs compression at the fracture site. **C**, Lateral radiograph made immediately postoperatively demonstrating definitive plate fixation. In this patient, the miniature fracture plate was left in place.

the plate may be more important than the number of cortices of fixation, and the increased spacing between screws provides advantages.^{17,18} Lindvall and Sagi¹⁸ said, “as fracture stabilization continues to evolve, the trend continues towards more strategic placement of implants with less total hardware.”

Some believe that use of a locking construct may be beneficial for management of osteoporotic bone or nonunion and for small, proximal or distal fracture fragments. Dual plating has also been advocated as an alternative fixation method for management of distal third humeral shaft fractures because it allows early, ag-

gressive motion without significant complications.¹⁹

Minimally Invasive Percutaneous Osteosynthesis

Recently, some authors have advocated the use of minimally invasive percutaneous osteosynthesis (MIPO) techniques for management of highly comminuted humeral shaft fractures. These techniques minimize disruption of fracture biology and limit the amount of dissection needed compared with that required for conventional plating. MIPO techniques are typically performed via an anterior approach, which protects the posteriorly located radial nerve.²⁰ Union rates ranging from 90% to 100% have been reported in two recent studies, with no reports of iatrogenic injury to the radial nerve.^{20,21} In a retrospective review that compared MIPO and ORIF for management of humeral shaft fracture, none of the 17 patients treated with MIPO had iatrogenic radial nerve palsy compared with 5 of 16 patients (31%) who underwent ORIF. In addition, functional outcomes with respect to shoulder and elbow function were similar in both groups.²² MIPO techniques appear to permit early recovery of motion in the shoulder and elbow.²³

Intramedullary Nailing

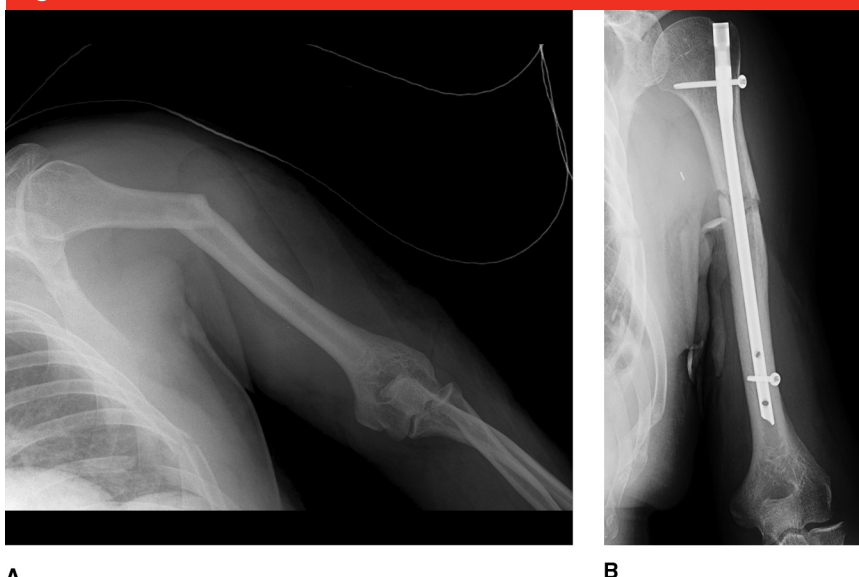
IM locked nails are load-sharing implants that allow preservation of periosteal blood supply and minimize disruption of fracture biology. Fracture fixation with flexible nails, Kirschner wires, or Enders nails are used less frequently secondary to difficulty in controlling rotation and axial forces with these devices. Patient positioning for antegrade IM nailing includes lateral (or semi-lateral), beach chair, or supine with a bump placed under the ipsilateral

scapula. Retrograde nailing is usually indicated for management of mid diaphyseal or proximal third fractures and, occasionally, distal third fractures of the humerus. It is most easily performed with the patient in a prone or lateral position.

Although union rates achieved with IM nailing of humeral shaft fractures (range, 87.5% to 97%) approach those of plating techniques, IM nailing of these fractures has been associated with shoulder pain and a high number of secondary procedures.^{5,24} Traditional approaches for nailing involve incising the rotator cuff, which may lead to shoulder pain or limited ROM postoperatively. Park et al²⁵ described an alternative approach for antegrade nailing in which an entry portal is made through the rotator interval to avoid damage to the hypovascular zone, irritation of the subacromial space, and, ultimately, poor shoulder function and pain scores. Retrograde nailing requires creation of an entry portal proximal to the olecranon fossa and may increase the risk of iatrogenic fracture secondary to aberrant entry portal placement and elbow pain secondary to surgery about the elbow. Lower infection rates have been reported with IM nailing of diaphyseal fractures of the humerus, and some studies have reported decreased iatrogenic injury to the radial nerve.⁵

With proper patient selection, good outcomes can be achieved using retrograde or antegrade nailing (Figure 5). In a prospective comparison of antegrade and retrograde nailing for mid shaft fractures of the humerus, Cheng and Lin²⁶ reported that time to union (11 weeks versus 12 weeks, respectively) and union rate (95% versus 93%, respectively) were similar. Rommens et al²⁴ reported excellent shoulder and elbow function following both antegrade and retrograde IM nailing for hu-

Figure 5



A

B

A, AP radiograph demonstrating a humeral shaft fracture in a polytraumatized patient with a crush injury and a poor soft-tissue envelope, as well as brachial plexus and vascular injuries. **B**, AP radiograph demonstrating initial fracture stabilization with an antegrade intramedullary nail. Given the soft-tissue injury, antegrade intramedullary nailing was thought to be the most appropriate management option.

meral fracture stabilization, whereas Changulani et al⁵ found that 4 of 23 patients (20%) with diaphyseal fracture treated with antegrade nailing had decreased shoulder function secondary to nail impingement at final follow-up, though no difference was found in shoulder functional outcome between the use of a plate and the use of an IM nail. Cheng and Lin²⁶ found that shoulder recovery following antegrade nailing was twice as long as that following retrograde nailing based on Neer shoulder scoring. However, elbow recovery following retrograde nailing was twice as long as that for antegrade nailing based on Mayo Elbow Performance Score.

IM Nailing versus ORIF

Several studies have compared IM nailing with compression plating for management of humeral shaft fractures. Changulani et al⁵ found that the rate of nerve injury was similar

in patients treated with IM nailing or dynamic compression plating. Of 23 patients in the nailing group, only one injury to the axillary nerve was reported. Of 24 patients in the plating group, one injury to the radial nerve was reported; however, infection was four times higher with plating than with nailing.⁵ This rate of infection has not been reported in other studies.

Singiseti and Ambedkar²⁷ found that plating was more reliable than IM nailing in terms of obtaining excellent to good results, as defined by ROM at the shoulder and elbow, lack of pain, and lack of disability. The authors reported delayed union in 10 of 20 patients (50%) treated with IM nails and a 15% incidence of shoulder dysfunction. In randomized prospective studies by McCormack et al²⁸ and Putti et al,²⁹ no significant difference in shoulder and elbow function was found in patients treated with IM nailing compared

Table 3**Indications for Radial Nerve Exploration in the Setting of Radial Nerve Palsy**

Open fracture
High-velocity gunshot or penetrating injury
Vascular injury
Nerve deficit after closed reduction ^a
Distal third (Holstein-Lewis) fractures ^a

^a Denotes controversial indication

with those treated with ORIF; however, the reoperation and complication rates were higher in the IM nailing group. In a recent meta-analysis of plate fixation versus IM nailing for humeral shaft fracture, Heine-man et al³⁰ noted that ORIF had a lower risk of complication than did IM nailing.

Regardless of technique, attention to detail is essential to avoid complications; shoulder pain may develop following antegrade nailing with poor technique, and nailing of a distracted fracture can lead to non-union. Inadequate fixation with gapping or distraction and aggressive retraction can damage the radial nerve and lead to suboptimal results following ORIF.

Special Considerations**Radial Nerve Palsy**

In a systematic review of more than 4,000 humeral shaft fractures, radial nerve palsy occurred in an average of approximately 11% of fractures.³¹ Incidence of radial nerve palsy was higher in distal fractures of the humerus than in proximal fractures, with an incidence of only 1.8% found in proximal third humeral shaft fractures compared with 23.6% for distal third fractures.³¹ The authors also found that transverse and spiral fractures were asso-

ciated with higher rates of nerve injury than were comminuted or oblique fractures. Interestingly, there was no statistically significant difference between open and closed fractures in terms of rate of radial nerve palsy.³¹ Spontaneous recovery occurred in 70% of patients in an average of 7 weeks (range, 2 weeks to 6.6 months).^{31,32}

Bishop and Ring³³ found that early observation was appropriate in patients with radial nerve palsy given that early surgical intervention did not appear to improve outcomes except in special circumstances, including open humeral fracture, concomitant forearm injury, or floating elbow. In these cases, there was <40% chance of nerve recovery; thus, early intervention was deemed appropriate.³³ Sonneveld et al³⁴ also compared early observation with early surgical intervention for management of humeral shaft fractures with associated injury to the radial nerve. In a series of 14 patients with humeral shaft fractures and nerve injuries who underwent early surgical exploration, 13 were found to have only contusion to the radial nerve. The authors reported similar rates of recovery in patients who underwent surgical exploration compared with those treated expectantly. In a systematic review of 1,045 patients with radial nerve palsy associated with humeral shaft fracture, Shao et al³¹ demonstrated similar trends in eventual recovery regardless whether early surgical exploration or expectant management was employed. Despite these findings, the fingers and wrist should be braced in extension during the observation period to help prevent flexion contracture. In addition, aggressive therapy should be initiated to ensure adequate ROM in the fingers and wrist.

Length of observation remains a subject of debate. Many consider 6 months to be the maximum duration

of expectant observation based on a nerve regeneration rate of 1 mm/day.³¹ If no return of function is seen in 2 to 3 months, electromyography (EMG) can be performed; however, some would consider performing EMG as early as 7 weeks postinjury.^{35,36} In patients with nerve injury, EMG findings at 6 weeks postinjury may include fibrillation potentials, positive sharp waves, and monophasic action potentials of short duration.³⁶ If signs of spontaneous recovery are present, repeat evaluation at approximately 12 weeks should demonstrate larger polyphasic action potentials, although there seems to be little reason to reevaluate patients who are improving.³⁶ A migrating Tinel sign on physical examination has also been shown to be a helpful prognostic indicator.³⁶

Certain clinical scenarios demand more aggressive management of radial nerve palsy (Table 3). The argument for exploration following open fracture stems from a study of 14 patients with radial nerve palsy and open fracture, 9 of whom had a lacerated or interposed nerve.³⁷ Other studies advocate exploration in the setting of a high-energy mechanism of injury. In a retrospective review of 24 patients with high-energy humeral shaft fractures and associated complete radial nerve palsy, 18 fractures were surgically explored, and 6 patients were found to have a transected radial nerve. Five of these patients underwent primary repair.³² At follow-up, however, none showed signs of recovery. Shao et al³¹ found that, at the time of late exploration, the nerve can be entrapped in 6% to 25% of cases and lacerated in 20% to 42%. Benefits of delayed surgical exploration include preventing unnecessary surgery and providing time for the nerve sheath to heal without early disruption in an environment conducive to healing. Disadvantages of late exploration include scarring

and decreased nerve mobility,³⁶ with some studies reporting worse outcomes.³⁸ In addition to direct nerve repair and grafting for management of radial nerve injury, common tendon transfers can be performed years after the initial injury to improve function.

Nonunion

Nonunion of humeral shaft fractures is relatively rare. When nonunion does occur, management requires identification of the underlying etiology. A nonunion work-up, as outlined by Brinker et al,³⁹ should be considered in the absence of technical error. Hypertrophic nonunions require increased stability at the fracture site, whereas atrophic nonunions require biologic stimulation. Type and use of bone graft is debatable; Hierholzer et al⁴⁰ achieved similar union rates using either iliac crest autograft or demineralized bone matrix along with rigid internal compression plating for management of atrophic nonunion. However, overall donor site morbidity associated with harvest of iliac crest autograft was 44%, and complications included infection and persistent pain. Other management options include autologous transplantation of concentrated bone marrow aspirate, use of fibular strut grafting for fracture site bridging to enhance screw purchase, and dynamic compression plating.⁴¹ Use of orthogonal plating may also be advantageous in some situations to increase stability during nonunion surgery.⁴²

External fixation (either uniplanar or circular) is a possible solution in the setting of nonunion caused by infection or bone loss.⁴³ Similar complication rates have been reported with plate fixation and bone grafting compared with both uniplanar and circular external fixation systems. In a retrospective study of 80 patients

with nonunion of the humeral shaft, Atalar et al⁴³ treated 35 patients with circular external fixators, 24 with a unilateral limb reconstruction system, and 21 with plate fixation. Bone union was achieved in >95% of all patients regardless of fixation method used. Tomić et al⁴⁴ reported similar results in 28 patients with atrophic nonunion treated with Ilizarov frame fixation; successful union was achieved in all 28 patients. In cases of nonunion caused by bone loss, bone shortening can be considered to achieve union.

Osteoporotic Fractures

Management of osteoporotic fractures of the humeral shaft can be challenging. Debates regarding optimal management of these fractures focus on the types of screws used and the necessary number of cortices and screws required per fracture segment. Hak et al⁴⁵ demonstrated that two locking screws per fracture segment provided sufficient stability in a simulated osteoporotic gapped-fracture model. This may be due in part to the plating concept of working length, in which increased fixation strength is noted with placement of screws close to the fracture, followed by plate fixation with screws spaced over a longer length plate. Using a Sawbones model (Pacific Research Laboratories, Vashon, WA) of osteoporotic bone, Gardner et al⁴⁶ compared the performance of a locked construct with that of a hybrid plate construct in which an unlocked screw was used to aid reduction and locked screws were later used to protect the reduction. Construct performance was similar at 10 cycles and during the remaining cycles, with comparable stiffness reported at 1,000 cycles. The addition of cortical screws to two locking screws placed proximal and distal to the fracture did not compromise the

biomechanical strength of the construct. The authors concluded that an all-locking plate construct may not be necessary for management of unstable osteoporotic fractures of the humeral shaft.

Summary

Functional bracing and nonsurgical management remain the standard of care for most humeral shaft fractures; however, surgical management is indicated in certain situations, including polytrauma and failure of nonsurgical treatment. Numerous techniques such as ORIF, MIPO, and IM nailing can be used to manage these fractures, and each technique has demonstrated excellent outcomes with careful patient selection. Radial nerve palsy, nonunion, and osteoporotic fractures can complicate management of humeral shaft fractures; however, acceptable outcomes can be achieved when these clinical entities are managed appropriately.

References

Evidence-based Medicine: Levels of evidence are described in the table of contents. In this article, references 5, 8, 26-29, 31, and 36 are level I studies. References 2, 4, 20, 21, 23, 25, 30, 33, 34, 41, 45, and 46 are level II studies. References 10, 11, 14-16, 22, 24, 37, 40, and 42 are level III studies. References 1, 6, 9, 12, 13, 17-19, 32, 38, 39, 43, and 44 are level IV studies.

References printed in **bold** type are those published within the past five years.

1. Ekholm R, Adami J, Tidermark J, Hansson K, Törnkvist H, Ponzer S: Fractures of the shaft of the humerus: An epidemiological study of 401 fractures. *J Bone Joint Surg Br* 2006;88(11):1469-1473.
2. Gerwin M, Hotchkiss RN, Weiland AJ:

- Alternative operative exposures of the posterior aspect of the humeral diaphysis with reference to the radial nerve. *J Bone Joint Surg Am* 1996;78(11):1690-1695.
3. Walker M, Palumbo B, Badman B, Brooks J, Van Gelderen J, Mighell M: **Humeral shaft fractures: A review.** *J Shoulder Elbow Surg* 2011;20(5):833-844.
 4. Zlotolow DA, Catalano LW III, Barron OA, Glickel SZ: Surgical exposures of the humerus. *J Am Acad Orthop Surg* 2006;14(13):754-765.
 5. Changulani M, Jain UK, Keswani T: Comparison of the use of the humerus intramedullary nail and dynamic compression plate for the management of diaphyseal fractures of the humerus: A randomised controlled study. *Int Orthop* 2007;31(3):391-395.
 6. Adili A, Bhandari M, Sprague S, Dunlop RB, Schemitsch EH: Humeral shaft fractures as predictors of intra-abdominal injury in motor vehicle collision victims. *Arch Orthop Trauma Surg* 2002;122(1):5-9.
 7. *The Comprehensive Classification of Fractures*. Bern, Switzerland, ME Muller Foundation, 1997.
 8. Sarmiento A, Waddell JP, Latta LL: Diaphyseal humeral fractures: Treatment options. *Instr Course Lect* 2002;51:257-269.
 9. Klenerman L: Fractures of the shaft of the humerus. *J Bone Joint Surg Br* 1966;48(1):105-111.
 10. Koch PP, Gross DF, Gerber C: The results of functional (Sarmiento) bracing of humeral shaft fractures. *J Shoulder Elbow Surg* 2002;11(2):143-150.
 11. Sarmiento A, Zagorski JB, Zych GA, Latta LL, Capps CA: Functional bracing for the treatment of fractures of the humeral diaphysis. *J Bone Joint Surg Am* 2000;82(4):478-486.
 12. Ekholm R, Tidermark J, Törnkvist H, Adami J, Ponzer S: Outcome after closed functional treatment of humeral shaft fractures. *J Orthop Trauma* 2006;20(9):591-596.
 13. Ring D, Chin K, Taghinia AH, Jupiter JB: Nonunion after functional brace treatment of diaphyseal humerus fractures. *J Trauma* 2007;62(5):1157-1158.
 14. Wallny T, Sagebiel C, Westerman K, Wagner UA, Reimer M: Comparative results of bracing and interlocking nailing in the treatment of humeral shaft fractures. *Int Orthop* 1997;21(6):374-379.
 15. Denard A Jr, Richards JE, Obremesky WT, Tucker MC, Floyd M, Herzog GA: **Outcome of nonoperative vs operative treatment of humeral shaft fractures: A retrospective study of 213 patients.** *Orthopedics* 2010;33(8). doi: 10.3928/01477447-20100625-16.
 16. Jawa A, McCarty P, Doornberg J, Harris M, Ring D: Extra-articular distal-third diaphyseal fractures of the humerus: A comparison of functional bracing and plate fixation. *J Bone Joint Surg Am* 2006;88(11):2343-2347.
 17. Crow BD, Mundis G, Anglen JO: Clinical results of minimal screw plate fixation of forearm fractures. *Am J Orthop (Belle Mead NJ)* 2007;36(9):477-480.
 18. Lindvall EM, Sagi HC: Selective screw placement in forearm compression plating: results of 75 consecutive fractures stabilized with 4 cortices of screw fixation on either side of the fracture. *J Orthop Trauma* 2006;20(3):157-162.
 19. Prasarn ML, Ahn J, Paul O, et al: **Dual plating for fractures of the distal third of the humeral shaft.** *J Orthop Trauma* 2011;25(1):57-63.
 20. Jiang R, Luo CF, Zeng BF, Mei GH: Minimally invasive plating for complex humeral shaft fractures. *Arch Orthop Trauma Surg* 2007;127(7):531-535.
 21. Zhiquan A, Bingfang Z, Yeming W, Chi Z, Peiyan H: Minimally invasive plating osteosynthesis (MIPO) of middle and distal third humeral shaft fractures. *J Orthop Trauma* 2007;21(9):628-633.
 22. An Z, Zeng B, He X, Chen Q, Hu S: **Plating osteosynthesis of mid-distal humeral shaft fractures: Minimally invasive versus conventional open reduction technique.** *Int Orthop* 2010;34(1):131-135.
 23. Kobayashi M, Watanabe Y, Matsushita T: Early full range of shoulder and elbow motion is possible after minimally invasive plate osteosynthesis for humeral shaft fractures. *J Orthop Trauma* 2010;24(4):212-216.
 24. Rommens PM, Kuechle R, Bord T, Lewens T, Engelmann R, Blum J: **Humeral nailing revisited.** *Injury* 2008;39(12):1319-1328.
 25. Park JY, Pandher DS, Chun JY, Md ST: **Antegrade humeral nailing through the rotator cuff interval: A new entry portal.** *J Orthop Trauma* 2008;22(6):419-425.
 26. Cheng HR, Lin J: **Prospective randomized comparative study of antegrade and retrograde locked nailing for middle humeral shaft fracture.** *J Trauma* 2008;65(1):94-102.
 27. Singiseti K, Ambedkar M: **Nailing versus plating in humerus shaft fractures: A prospective comparative study.** *Int Orthop* 2010;34(4):571-576.
 28. McCormack RG, Brien D, Buckley RE, McKee MD, Powell J, Schemitsch EH: Fixation of fractures of the shaft of the humerus by dynamic compression plate or intramedullary nail: A prospective, randomized trial. *J Bone Joint Surg Br* 2000;82(3):336-339.
 29. Putti AB, Uppin RB, Putti BB: **Locked intramedullary nailing versus dynamic compression plating for humeral shaft fractures.** *J Orthop Surg (Hong Kong)* 2009;17(2):139-141.
 30. Heineman DJ, Poolman RW, Nork SE, Ponsen KJ, Bhandari M: **Plate fixation or intramedullary fixation of humeral shaft fractures.** *Acta Orthop* 2010;81(2):216-223.
 31. Shao YC, Harwood P, Grotz MR, Limb D, Giannoudis PV: Radial nerve palsy associated with fractures of the shaft of the humerus: A systematic review. *J Bone Joint Surg Br* 2005;87(12):1647-1652.
 32. Ring D, Chin K, Jupiter JB: Radial nerve palsy associated with high-energy humeral shaft fractures. *J Hand Surg Am* 2004;29(1):144-147.
 33. Bishop J, Ring D: **Management of radial nerve palsy associated with humeral shaft fracture: A decision analysis model.** *J Hand Surg Am* 2009;34(6):991-996, e1.
 34. Sonneveld GJ, Patka P, van Mourik JC, Broere G: Treatment of fractures of the shaft of the humerus accompanied by paralysis of the radial nerve. *Injury* 1987;18(6):404-406.
 35. DeFranco MJ, Lawton JN: Radial nerve injuries associated with humeral fractures. *J Hand Surg Am* 2006;31(4):655-663.
 36. Elton SG, Rizzo M: **Management of radial nerve injury associated with humeral shaft fractures: An evidence-based approach.** *J Reconstr Microsurg* 2008;24(8):569-573.
 37. Foster RJ, Swiontkowski MF, Bach AW, Sack JT: Radial nerve palsy caused by open humeral shaft fractures. *J Hand Surg Am* 1993;18(1):121-124.
 38. Amillo S, Barrios RH, Martínez-Peric R, Losada JL: Surgical treatment of the radial nerve lesions associated with fractures of the humerus. *J Orthop Trauma* 1993;7(3):211-215.
 39. Brinker MR, O'Connor DP, Monla YT, Earthman TP: Metabolic and endocrine abnormalities in patient with nonunions. *J Orthop Trauma* 2007;21(8):557-570.
 40. Hierholzer C, Sama D, Toro JB, Peterson M, Helfet DL: Plate fixation of ununited humeral shaft fractures: Effect of type of bone graft on healing. *J Bone Joint Surg Am* 2006;88(7):1442-1447.
 41. Vidyadhara S, Vamsi K, Rao SK,

- Gnanadoss JJ, Pandian S: Use of intramedullary fibular strut graft: A novel adjunct to plating in the treatment of osteoporotic humeral shaft nonunion. *Int Orthop* 2009;33(4):1009-1014.
42. Rubel IF, Kloen P, Campbell D, et al: Open reduction and internal fixation of humeral nonunions: A biomechanical and clinical study. *J Bone Joint Surg Am* 2002;84(8):1315-1322.
43. Atalar AC, Kocaoglu M, Demirhan M, Bilsel K, Eralp L: Comparison of three different treatment modalities in the management of humeral shaft nonunions (plates, unilateral, and circular external fixators). *J Orthop Trauma* 2008;22(4):248-257.
44. Tomić S, Bumbasirević M, Lesić A, Mitković M, Atkinson HD: Ilizarov frame fixation without bone graft for atrophic humeral shaft nonunion: 28 patients with a minimum 2-year follow-up. *J Orthop Trauma* 2007;21(8):549-556.
45. Hak DJ, Althausen P, Hazelwood SJ: Locked plate fixation of osteoporotic humeral shaft fractures: Are two locking screws per segment enough? *J Orthop Trauma* 2010;24(4):207-211.
46. Gardner MJ, Griffith MH, Demetrakopoulos D, et al: Hybrid locked plating of osteoporotic fractures of the humerus. *J Bone Joint Surg Am* 2006;88(9):1962-1967.